



Short Communication

First case of postmortem study in a patient vaccinated against SARS-CoV-2



Torsten Hansen^{a,*}, Ulf Titze^a, Nidhi Su Ann Kulamadayil-Heidenreich^b, Sabine Glombitza^c, Johannes Josef Tebbe^b, Christoph Röcken^d, Birte Schulz^a, Michael Weise^b, Ludwig Wilkens^c

^a Institute of Pathology, University Hospital OWL of the University of Bielefeld, Campus Lippe, Detmold, Germany

^b Department of Internal Medicine, Gastroenterology and Infectious Medicine, University Hospital OWL of the University of Bielefeld, Campus Lippe, Detmold, Germany

^c Institute of Pathology, KRH Hospital Nordstadt, Hannover, Germany

^d Institute of Pathology of the University of Schleswig-Holstein, Campus Kiel, Germany

ARTICLE INFO

Article history:

Received 25 February 2021

Received in revised form 13 April 2021

Accepted 14 April 2021

Keywords:

SARS-CoV-2

Vaccine

Autopsy

Histology

RT-PCR

ABSTRACT

A previously symptomless 86-year-old man received the first dose of the BNT162b2 mRNA COVID-19 vaccine. He died 4 weeks later from acute renal and respiratory failure. Although he did not present with any COVID-19-specific symptoms, he tested positive for SARS-CoV-2 before he died. Spike protein (S1) antigen-binding showed significant levels for immunoglobulin (Ig) G, while nucleocapsid IgG/IgM was not elicited. Acute bronchopneumonia and tubular failure were assigned as the cause of death at autopsy; however, we did not observe any characteristic morphological features of COVID-19. Postmortem molecular mapping by real-time polymerase chain reaction revealed relevant SARS-CoV-2 cycle threshold values in all organs examined (oropharynx, olfactory mucosa, trachea, lungs, heart, kidney and cerebrum) except for the liver and olfactory bulb. These results might suggest that the first vaccination induces immunogenicity but not sterile immunity.

© 2021 The Author(s). Published by Elsevier Ltd on behalf of International Society for Infectious Diseases. This is an open access article under the CC BY-NC-ND license (<http://creativecommons.org/licenses/by-nc-nd/4.0/>).

We report on an 86-year-old male resident of a retirement home who received vaccine against SARS-CoV-2. Past medical history included systemic arterial hypertension, chronic venous insufficiency, dementia and prostate carcinoma. On January 9, 2021, the man received lipid nanoparticle-formulated, nucleoside-modified RNA vaccine BNT162b2 in a 30 µg dose. On that day and in the following 2 weeks, he presented with no clinical symptoms (Table 1). On day 18, he was admitted to hospital for worsening diarrhea. Since he did not present with any clinical signs of COVID-19, isolation in a specific setting did not occur. Laboratory testing revealed hypochromic anemia and increased creatinine serum levels. Antigen test and polymerase chain reaction (PCR) for SARS-CoV-2 were negative.

Gastroscopy and colonoscopy were performed to investigate the cause of diarrhea further. Colonoscopy, in particular, demonstrated an ulcerative lesion of the left colonic flexure, which was

histologically diagnosed as ischemic colitis. PCR-analysis on biopsy specimens, following a previously reported method (Kaltschmidt et al., 2021), was negative for SARS-CoV-2. Treatment was supportive with mesalazine and intravenous iron substitution. Subsequently, the patient's condition deteriorated under the development of renal insufficiency. On day 24, a patient in the same hospital room as our case tested positive for SARS-CoV-2. On day 25, our patient tested SARS-CoV-2 positive by real-time PCR (RT-PCR), with a low cycle threshold (Ct) value indicating high virus load. On further analysis of the swab sample, there was no evidence for mutant SARS-CoV-2 variants B.1.1.7, B.1.351 or B.1.1.28.1. Taken together, it appears the patient became infected from the patient in his hospital room. Our patient now presented with fever and respiratory discomfort, and lung auscultation displayed crackles. Despite starting supplemental oxygen (2 l per minute) and antibiotic therapy by ceftriaxone, the patient died from acute renal and respiratory failure on the following day.

Immunogenicity assessment by measuring spike protein (S1) antigen-binding immunoglobulin (Ig) G in the serum samples obtained at day 25 showed antibody response (8.7 U/ml, reference value <0.8–1.2 U/ml; Roche ECLIATM), while (nucleocapsid) NCP-

* Corresponding author at: Institute of Pathology, University Hospital OWL of the University of Bielefeld, Campus Lippe, Röntgenstr. 18, D-32756 Detmold, Germany. E-mail address: Torsten.Hansen@klinikum-lippe.de (T. Hansen).

Table 1
Summary of major features of the patient's history, clinical symptoms and laboratory findings, including SARS-CoV-2 testing (reference values given in brackets).

Major event	Day 1	Day 15	Day 18	Day 19	Day 20	Day 23	Day 24	Day 25	Day 26
Vaccination	No relevant symptoms recorded	Collapse during breakfast	Admission to hospital; gastroscopy (mild gastritis)	Abdominal ultrasound, initiating intravenous iron application	Colonoscopy (ischemic colitis), initiating mesalazine	Acute renal insufficiency, initiating intravenous glucose application	Patient in same hospital room has positive SARS-CoV-2 RT-PCR test (Ct, 15)	Patient somnolent, initiating antibiotic therapy, chest radiograph with minimal infiltrates	Death at 14:30
Leading clinical symptoms	No relevant symptoms recorded	No further relevant symptoms recorded	Diarrhea	Anemia	Anemia	Lung auscultation with any pathological signs, hypernatremia	Hypernatremia	Dehydration, lung auscultation with crackles	Acute renal and respiratory failure
Temperature (°C)	Not recorded	Not recorded	36.4	Not recorded	Not recorded	36.8	36.2	38.8	Not recorded
Blood pressure (mmHg)	Not recorded	130/70	187/83	Not recorded	Not recorded	180/80	166/73	160/80	Not recorded
Oxygen saturation (SpO ₂)	Not recorded	Not recorded	97%	Not recorded	Not recorded	Not recorded	Not recorded	97% + 2l O ₂	Not recorded
SARS-CoV-2 test	No data	No data	Antigen-test: negative PCR-test: negative	No data	PCR-test: negative	No data	No data	RT-PCR-test: positive (Ct, 20)	No data
White-cell count (4–9/nl)	No data	No data	6.6	7.1	12.1	13.5	No data	9.2	15.2
Platelet count (140–400/nl)	No data	No data	267	263	262	254	No data	204	196
Hemoglobin (140–18.0 g/dl)	No data	No data	7.4	7.1	7.2	8.0	No data	8.6	9.3
Lactate dehydrogenase (135–250 U/l)	No data	No data	179	165	No data	No data	No data	No data	439
Creatinine (0.7–1.2 mg/dl)	No data	No data	1.91	1.78	No data	2.04	No data	2.17	3.23
C-reactive protein (<0.5 mg/dl)	No data	No data	1.0	0.8	No data	2.0	No data	No data	8.8
Sodium (135–145 mmol/l)	No data	No data	138	138	No data	154	155	No data	156

RT-PCR, real-time polymerase chain reaction; Ct, cycle threshold.

IgG/IgM was not elicited (<0.1 U/ml, reference value >1.0 U/ml; Roche ECLIA™). These results indicate that the patient had already developed relevant immunogenicity through vaccination.

Postmortem study revealed acute bilateral bronchopneumonia with abscesses, sometimes being surrounded by bacterial cocci (Figure 1). There were no findings of commonly described manifestations of COVID-19-associated pneumonitis. In the heart, we found biventricular hypertrophy (weight 580 g) and histologically, we diagnosed ischemic cardiomyopathy. We detected amyloidosis of the transthyretin type in the heart and to a lesser extent in the lungs. The kidneys revealed both chronic damage with arteriolosclerosis and interstitial fibrosis, and acute renal failure with hydropic tubular degeneration. The examination of the brain revealed a left parietal pseudocystic tissue necrosis, which was diagnosed as an old infarction area.

We conducted molecular mapping of 9 different anatomical parts of formalin-fixed paraffin-embedded tissue as previously described (Kaltschmidt et al., 2021). RNA was extracted from paraffin sections using the Maxwell RSC (Promega, Madison, WI, USA). Multiplex RT-PCR analysis targeted 2 independent genes of the SARS-CoV-2-genome (Fluorotype SARS-CoV-2 plus Kit; HAIN/Bruker, Nehren, Germany); RNA-dependent RNA polymerase (Target 1) and nucleopeptide (Target 2). The negative cut-off value was Ct >45. We examined 9 different tissue samples for known and relevant pathways of virus spreading in the human body (Figure 1). To prevent cross-contamination, each specimen was directly embedded in separate tissue cassettes and separately fixed in 4% phosphate-buffered saline-buffered formalin. We demonstrated viral RNA in nearly all organs examined except for the liver and the olfactory bulb (Figure 1).

A detailed autopsy study including molecular virus mapping of a patient vaccinated against SARS-CoV-2 with a positive SARS-CoV-2 test post-vaccination has not previously been reported, to the authors' knowledge. We suggest that a single treatment with BNT162b2 RNA vaccine elicited significant immunogenicity, as reflected in the reported spike protein-based neutralizing IgG serum values. From the weeks before vaccination, through vaccination (day 1), to shortly before death (day 24), the patient was free of any clinical symptoms typically ascribed to COVID-19. Furthermore, blood work did not show an IgM titer that is generally observed 7–14 days after symptom onset (Kim et al., 2020). However, the patient tested SARS-CoV-2 positive. Both the Ct value measured in nasopharyngeal swab and values measured in formalin-fixed paraffin-embedded autopsy specimens indicate viral load and suggest transmissibility. Because our patient died approximately 2 days after his first positive SARS-CoV-2 test result, we suppose that the molecular mapping data reflects an early stage of viral infection. An early stage of infection might also explain why different regions such as the olfactory bulb and liver were not (yet) affected by systemic viral spread.

We did not observe any characteristic morphological features of COVID-19 reported in comprehensive morphological autopsy studies so far (Schaller et al., 2020; Edler et al., 2020; Ackermann et al., 2020). We did not find any typical signs of diffuse alveolar damage in the lungs, but we identified extensive acute bronchopneumonia, possibly of bacterial origin. We concluded that the patient died from bronchopneumonia and acute renal failure.

Our findings are in line with previous evidence from animal models that immunization against SARS-CoV-2 by vaccination appeared to reduce the severity of pathogenesis, especially with regard to severe lung disease, while viral RNA persisted in nasal swabs (Van Doremalen et al., 2020; Vogel et al., 2021). Recently, Amit et al. (2021) published results on a clinical trial on

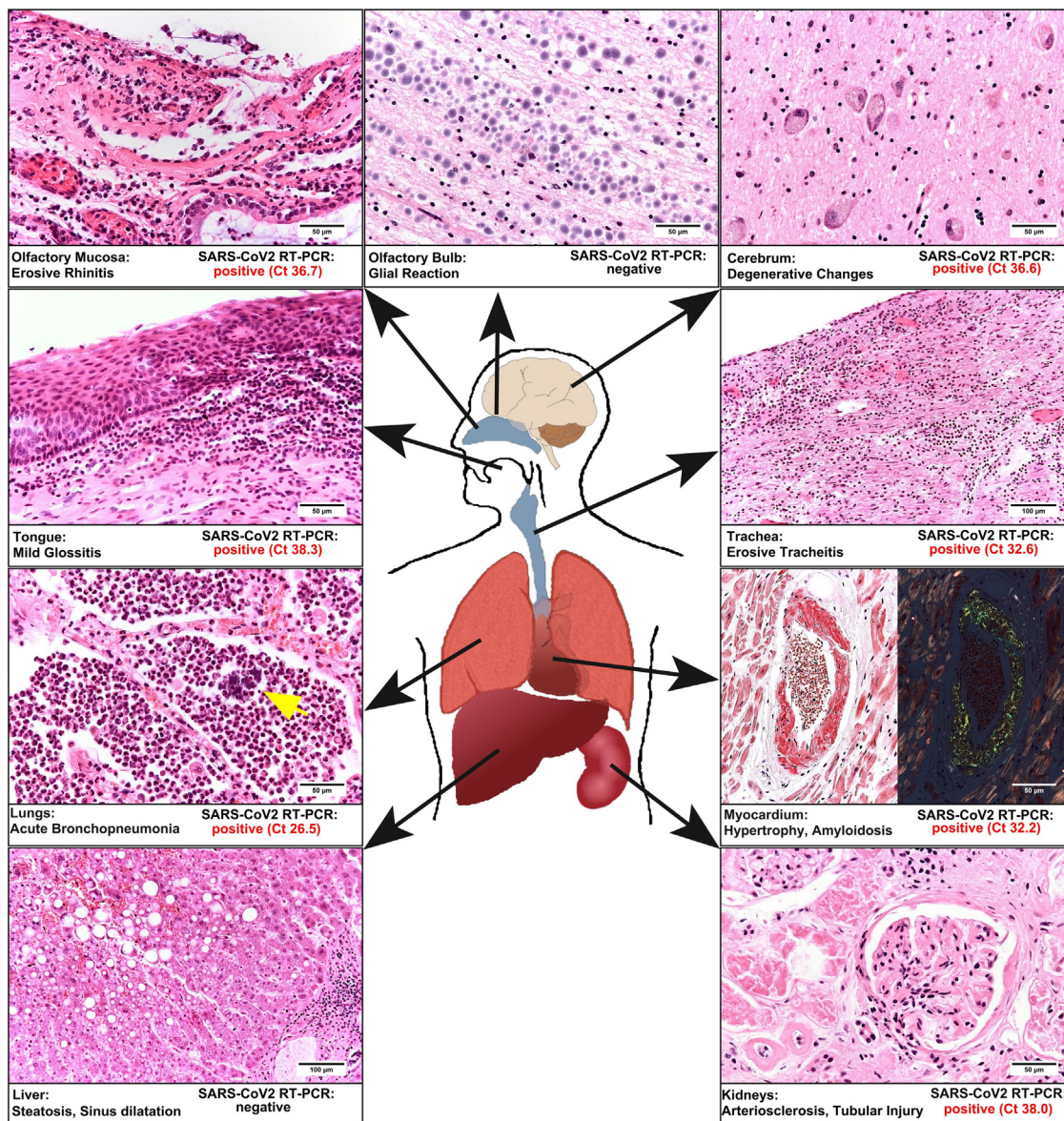


Figure 1. Synopsis of the relevant histological findings and the results of molecular mapping is presented. The histomorphology is obtained by standard hematoxylin and eosin reaction, except for the myocardium on the right side (Congo red staining). The magnification is shown by bars. Note that in the lungs, we also observed colonies of cocci (arrow) in granulocytic areas. In addition, the results of molecular mapping are given as evaluated cycle threshold values of the real-time polymerase chain reaction for SARS-CoV-2. Note that only in the olfactory bulb and the liver SARS-CoV-2 could not be detected.

healthcare workers using vaccine BNT162b2 that demonstrated substantial early reductions in SARS-CoV-2 infection and symptomatic COVID-19 rates following administration of the first vaccine dose.

Concerning major adverse effects in patients receiving vaccination against SARS-CoV-2, local effects predominate, and severe systemic reactions are rarely described (Yuan et al., 2020). However, recent reports of an increased risk of blood clots, particularly of cerebral venous sinus thrombosis in the case of the Oxford-AstraZeneca vaccine (Mahase 2021), raised a matter of debate on the safety of COVID-19 vaccine in general. Comprehensive analysis of autopsy data must be performed to provide more detailed insights into lethal adverse effects and any deaths associated with vaccination.

In summary, the results of our autopsy case study in a patient with mRNA vaccine confirm the view that by first dose of vaccination against SARS-CoV-2 immunogenicity can already be induced, while sterile immunity is not adequately developed.

Conflicts of interest

The authors do not have any commercial or financial conflict of interest.

Ethical approval

This case study was performed in the setting of the German national “Defeat Pandemics” project, approved by the Medical Association of Westphalia-Lippe, Münster, Germany (Ref. 2020-575-b-S) and carried out in accordance with the ethical principles of the Helsinki Declaration. Informed consent by the next-of-kin was available.

Funding source

There was no funding received from any individual or organization.

Acknowledgements

We are grateful for the expert technical assistance of Ralf Bode and Nadine Weber (University Hospital of OWL of the University of Bielefeld, Campus Lippe, Detmold).

References

- Ackermann M, Verleden SE, Kuehnel M, Haverich A, Welte T, Laenger F, et al. Pulmonary vascular endothelialitis, thrombosis, and angiogenesis in Covid-19. *N Engl J Med* 2020;383:120–8, doi:<http://dx.doi.org/10.1056/NEJMoa2015432>.
- Amit S, Regev-Yochay G, Afek A, Kreiss Y, Leshem E. Early rate reductions of SARS-CoV2-infection and COVID-19 in BNT162b2 vaccine recipients. *Lancet* 2021;397(10277):875–7, doi:[http://dx.doi.org/10.1016/S0140-6736\(21\)00448-7](http://dx.doi.org/10.1016/S0140-6736(21)00448-7).
- Edler C, Schröder AS, Aepfelbacher M, Fitzek A, Heinemann A, Heinrich F, et al. Dying with SARS-CoV2 infection – an autopsy study of the first consecutive 80 cases in Hamburg, Germany. *Int J Legal Med* 2020;134:1275–84, doi:<http://dx.doi.org/10.1007/s00414-020-02336-7>.
- Kaltschmidt B, Fitzek ADE, Schaedler J, Förster C, Kaltschmidt C, Hansen T, et al. Hepatic vasculopathy and regenerative responses of the liver in fatal cases of COVID-19. *Clin Gastroenterol Hepatol* 2021;, doi:<http://dx.doi.org/10.1016/j.cgh.2021.01.044> In press.
- Kim DS, Rowland-Jones S, Gea-Mallorqui E. Will SARS-CoV-2 infection elicit long-lasting protective or sterilizing immunity? Implications for vaccine strategies. *Front Immunol* 2020;11:571481, doi:<http://dx.doi.org/10.3389/fimmu.2020.571481>.eCollection2020.
- Mahase E. Covid-19: AstraZeneca vaccine is not linked to increased risk of blood clots, finds European Medicine Agency. *BMJ* 2021;372:n774, doi:<http://dx.doi.org/10.1136/bmj.n774>.
- Schaller T, Hirschtbühl K, Burkhardt K, Braun G, Trepel M, Märkl B, et al. Postmortem examinations of patients with COVID19. *JAMA* 2020;323:2518–20, doi:<http://dx.doi.org/10.1001/jama.2020.8907>.
- Van Doremalen N, Lambe T, Spencer A, Belij-Rammersdorfer S, Purushotham JN, Port JR, et al. ChAdOx1 nCoV-19 vaccine prevents SARS-CoV-2 pneumonia in rhesus macaques. *Nature* 2020;586:578–82, doi:<http://dx.doi.org/10.1016/2020.05.13.093195>.
- Vogel AB, Kanevsky I, Che Y, Swanson KA, Muik A, Vormehr M, et al. Immunogenic BNT162b vaccines protect rhesus macaques from SARS-CoV-2. *Nature* 2021;592(7853):283–9, doi:<http://dx.doi.org/10.1101/2020.12.11.421008>.
- Yuan P, Ai P, Liu Y, Ai Z, Wang Y, Cao W, et al. Safety, tolerability, and immunogenicity of COVID19 vaccines: a systematic review and meta-analysis. *medRxiv* 2020;, doi:<http://dx.doi.org/10.1101/2020.11.03.20224998> Preprint.